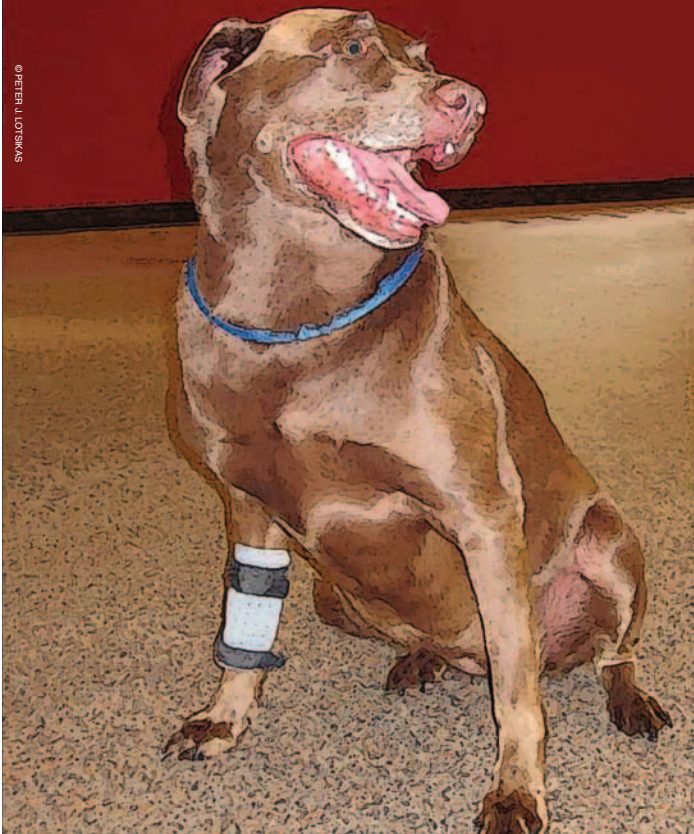



A Review of Canine Cruciate Disease

Part 1

By Peter J. Lotsikas, DVM, Diplomate ACVS, Lisa M. Fair, CMT, CCRT (Candidate), Faith M. Lotsikas, DVM, CCRT

Cranial cruciate ligament (CCL) deficiency is the most common cause of hind limb lameness in the canine and is estimated to affect one million dogs annually. The canine CCL is analogous to the anterior cruciate ligament (ACL) in humans; however, there are significant differences in the biomechanics of the human knee and canine stifle (knee) and the way in which deficiencies occur between the two species. In humans, the primary cause of an ACL injury is an acute, traumatic, typically sports-related event. Although CCL injury in dogs can occur in a similar manner, it is more often the result of a progressive degenerative process termed cranial cruciate disease. This etiological distinction must be considered when discussing the management of the condition. Despite the high prevalence and the long-standing history of this condition, we still do not fully understand its etiology. Furthermore, although several treatment options exist, no one method has been found to be *the* superior treatment for all cases. While the subject matter is vast, we hope to clarify the current understanding of this condition.

Anatomy

The stifle joint is stabilized by both passive constraints (ligaments, menisci, joint capsule) and active constraints (muscles and tendons). The CCL is the primary passive stabilizer of the stifle joint. It is composed of two bands, the craniomedial band that is taut in all phases of flexion and extension of the knee, and the caudolateral band that is taut in extension, but lax in flexion. Together, these bands limit internal rotation, hyperextension, and cranial tibial translation (forward motion of the tibia in relation to the femur). A major difference between dogs and humans is the way in which forces are transmitted through the limbs during weight bearing. When a human is standing, minimal force is placed on the anterior cruciate ligament. However, because dogs stand on their toes with a flexed stifle, their

cruciate ligament is continuously under load. Another anatomical difference is the angle of the top of the tibia, called the tibial plateau angle or slope. In humans, this slope is relatively flat. In dogs, this slope can vary between 14°-60°. When the canine knee is weight bearing, the tibia is displaced forward as the femur slides down the slope of the tibia, much like a car without brakes slides down a hill. The steeper the angle, the more significant the force. This is called tibial shear force. In a healthy stifle, the CCL opposes this motion. The integrity of the CCL is most easily assessed by the extent of cranial tibial translation present in the stifle joint. This movement can be elicited on physical exam of a CCL-deficient limb with manual manipulation,

referred to as a cranial-drawer or tibial-thrust test. A full tear of the CCL allows for this movement in both flexion and extension of the knee. In the event of a partial tear, it is typically the craniomedial band that is affected, in which case cranial tibial translation is present only when the stifle is in flexion.

A meniscus is a crescent-shaped, cartilaginous tissue that partially divides the articular surfaces of a joint. There are two menisci, a medial (inner) and lateral (outer), within the stifle joint. See **Figure 1**. These structures distribute load during weight bearing and provide structural integrity to the stifle as it undergoes tension and torsion. The menisci also play an important role in joint nutrition and lubrication. Both menisci are anchored to the tibial plateau. The medial meniscus has a firm attachment to the tibia and medial collateral ligament, while the lateral meniscus has a loose attachment to the tibia and an additional attachment to the femur. These differences allow for mobility of the lateral meniscus and limit mobility of the medial meniscus with cranial tibial translation. As a result, the medial meniscus is more vulnerable to injury when cruciate deficiency is present. Meniscal injury further increases the inflammation, pain, and lameness in an unstable stifle.

Pathology

A joint is an organ and proper function relies on healthy tissues and accurate structure orientation. The question remains whether cranial cruciate disease is initiated due to abnormal forces on a normal joint, normal forces exerted on an abnormal joint, or a combination of factors involving both. Regardless, once the cascade of cranial cruciate disease has begun, the ligament is vulnerable to rupture, even from normal activities.

Traumatic rupture of a healthy CCL occurs when the ligament's breaking strength is exceeded, or when an abnormal force is placed on a normal joint. This is typically caused by events, such as stepping into a hole or sudden turns when running, where hyperextension and excessive internal rotation can occur. Jumping can also result in an acute tear of the CCL. This manner of injury is seen in about 10% of my patient population.

More often, CCL injuries occur when normal force is exerted on an abnormal joint. What causes the joint to become "abnormal" appears to be multifactorial in origin. Proposed underlying etiologies for this chronic disease include both biological and biomechanical factors. Biological factors affecting the stifle

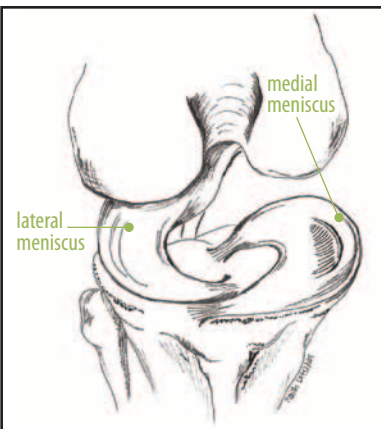


Figure 1: This illustration demonstrates the position and attachments of the menisci. Note that the lateral meniscus has a firm attachment to both the femur and the tibia. Courtesy of Dr. Faith Lotsikas



CanineIcer

Bringing years of equine sports medicine to the dog world

GROIN ICER



Canine Icers allow you to systematically apply ice packs to the major joints and muscles of your dog. When used following an injury or surgery, they can speed recovery by reducing swelling through a consistent and even application of ice. Canine Icers come in a full jacket style as well as joint wraps and may also be used for heat and magnetic therapies.

NECK ICER



SHOULDER ICER



PAW ICER



STIFLE ICER



HIP ICER



HOCK ICER





joint include development, genetics, metabolic function, hormonal influences, infection, immune mediated processes, and appropriate cellular production and turnover. Biomechanical components include muscular function and forces, alignment, conformation, movement, and joint contacts and pressures.

In addition, a dog that ruptures a CCL in one knee has a 50%-60% chance of rupturing the CCL in the other knee. Ultimately, cranial cruciate disease leads to osteoarthritis, inflammation, pain, lameness, and organ dysfunction. Further, the resulting instability increases the risk of injury to other structures within the stifle, most commonly a tear of the medial meniscus.

Predisposition

Cranial cruciate disease can affect dogs of any breed, sex, or age, although a higher incidence is reported for large breed and overweight dogs. Ligament degeneration is also associated with aging, which occurs earlier in large breed dogs versus small breed dogs. In addition, breeds including the Labrador Retriever, Newfoundland, Rottweiler, Mastiff, American Staffordshire Terrier, Akita, Boxer, and Bulldog appear to be overrepresented, which supports the likelihood of a genetic component. To date, the only breed group that has identified chromosomal abnormalities associated with the characteristic traits of cruciate disease is the Newfoundland. Certain conformation types (such as an upright stance or marked outward bowing hind limbs) also have an increased incidence of occurrence. In addition, neutered males and spayed females are at increased risk compared with their intact counterparts.

Clinical Presentation

Dogs with CCL injury can present with a multitude of varying clinical signs depending on the nature of the tear (acute vs. chronic, complete vs. partial), degree of osteoarthritis present, and if both legs are affected simultaneously.

An acute rupture due to a single traumatic event will initially cause a toe-touching to non-weight-bearing lameness that may improve temporarily with rest. Should a concurrent meniscal tear be present, the lameness tends to remain more persistent.

In some chronic cases, a precipitating event may be associated with an acute notable change in limb use; however, further investigation often reveals a history of intermittent lameness over a period of several weeks to months. In most cases, the complaint is a prolonged weight-bearing lameness that has become more severe. Other common observations include sitting with the affected limb extended or kicked out laterally rather than tucked under the body (see **Figure 2**), leaning or shifting weight





Figure 2: Positive sit test. Note that the patient is not sitting square, but rather holding the affected limb out to the side. Courtesy of Dr. Peter J. Lotsikas

ing or shifting weight



Worry about
your run,
not your
shoelaces

Get improved fit and comfort without buying new shoes. Lock Laces combine specially designed elastic laces with a spring-activated locking device. Wear with all styles of running shoes, athletic shoes, and casual lace-up shoes. Available in six colors.

Just slip your shoes on and off—no more laces or double knots to tie!

Clean Run®
www.cleanrun.com

Looking for a Solution
to Your Weaving Woes?

We've got the poles
and the DVD...



Available from

Clean Run®
www.cleanrun.com

off the affected limb when standing, and stiffness upon rising. In dogs with concurrent meniscal injury, an audible click may be noted when walking or flexing the stifle.

Partial CCL tears typically present with a complaint of a mild weight-bearing lameness following heavy exercise, or “stiffness” following prolonged periods of rest. Owners often report that their dog tends to “warm out of it” as the day progresses. The lameness usually resolves with restricted activity but returns following another event of heavy exercise. As the CCL continues to tear and the stifle becomes increasingly unstable, the lameness becomes more severe and persistent.

Dogs with both limbs affected may shift weight back and forth between the hind limbs when standing, shift weight forward to the forelimbs, have difficulty or be slow to sit and rise, and may be exercise intolerant. In some cases, the dog may be unable or unwilling to bear weight in either hind limb. This presentation can delay accurate diagnosis, as it may be confused with a neurological condition or solely attributed to concurrent hip dysplasia.

Diagnosis

Diagnosis of CCL rupture is straightforward when the patient presents with the classical history, lameness, radiographic appearance, and physical examination findings. See **Figure 3**. However, some dogs with chronic cranial cruciate disease or partial CCL tears do not have significant palpable stifle instability. This is often the case in performance dogs. In these cases, additional diagnostic tests, such as arthrocentesis, magnetic imaging (MRI), and/or arthroscopy may be recommended. Arthrocentesis involves using a sterile needle and syringe to collect joint fluid. Analysis of the cellular makeup of the joint fluid can help distinguish between a CCL tear, an underlying infection, tick-borne disease, or an immune-mediated joint disease. MRI allows for detailed imaging of soft-tissue structures within the stifle and can detect even subtle pathology of the cruciates and menisci. Arthroscopy is a minimally invasive technique that allows for a live magnified high-resolution assessment of the structures within the stifle joint. Should an injury be confirmed, stabilization may be performed at that time, under one anesthetic event. See **Figure 4**.

In the second part of this article we will present current concepts and techniques for the treatment of canine cruciate disease. 🐾

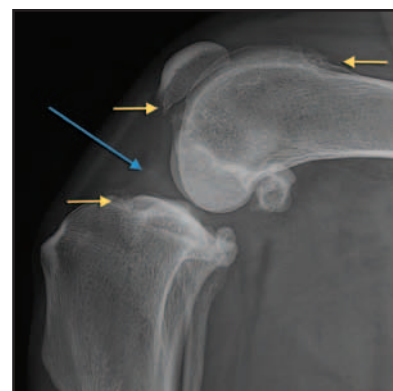


Figure 3: Lateral X-ray of a stifle with a complete cranial cruciate ligament. While the ligament cannot be seen on X-rays, classic secondary changes include water on the knee (blue arrow) and osteoarthritis (yellow arrows).
Courtesy of Dr. Peter J. Lotsikas

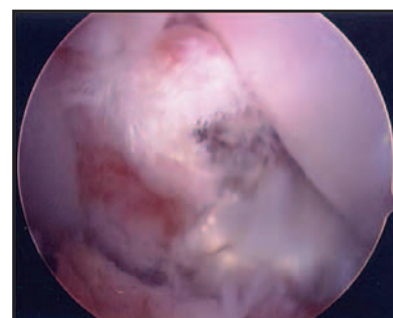
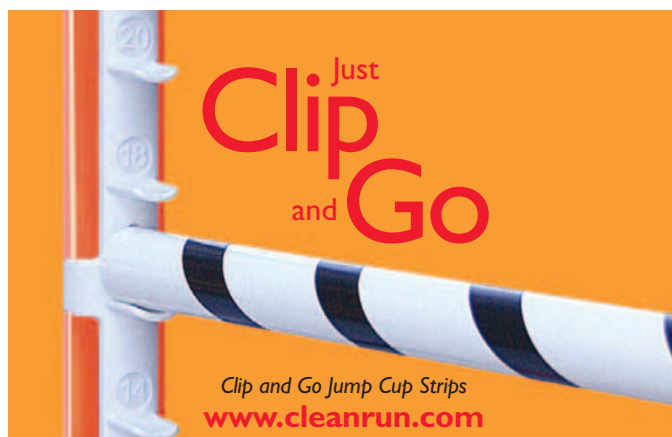


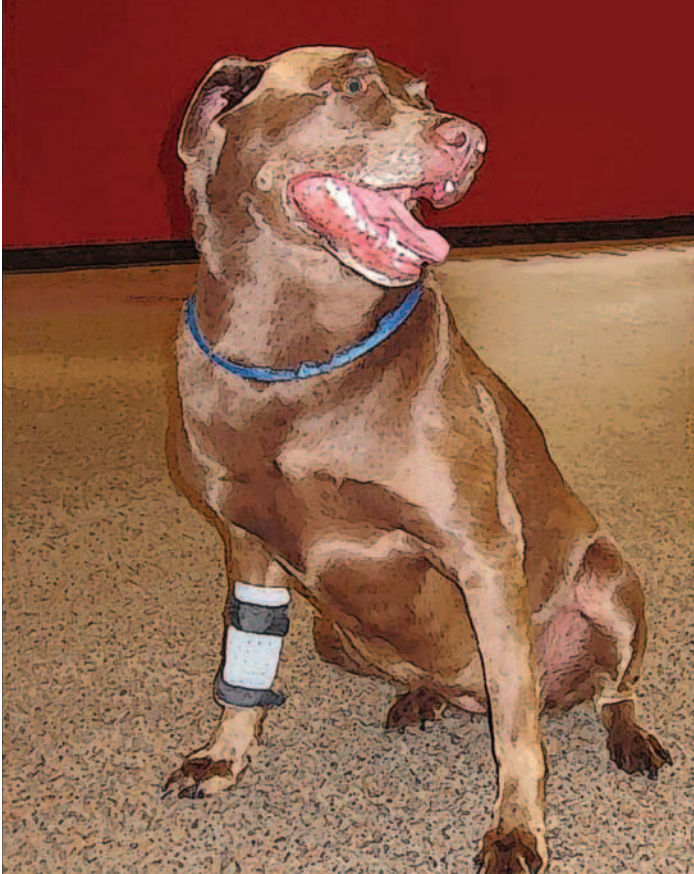Figure 4: Arthroscopic picture of a complete cranial cruciate ligament tear.
Courtesy of Dr. Jimi Cook.

Dr. Peter Lotsikas is a Diplomate of the American College of Veterinary Surgeons. He graduated with a BS degree in Biology from Virginia Tech and a DVM degree from the Virginia-Maryland Regional College of Veterinary Medicine. He then completed a general small animal internship at Kansas State University, followed by a surgical internship at Dallas Veterinary Surgical Center. Dr. Lotsikas received his formal surgical residency training at Iowa State University. He now practices at the Veterinary Orthopedic & Sports Medicine Group (VOSM) in Annapolis Junction, Maryland. Additional information about Dr. Lotsikas is available at www.VOSM.com

Dr. Faith Lotsikas earned her veterinary degree from the Virginia Maryland Regional College of Veterinary Medicine. She has always had a strong interest in whole pet wellness. For that reason, she became a certified canine rehabilitation therapist through the Canine Rehabilitation Institute. She now practices with her husband at the Veterinary Orthopedic & Sports Medicine Group (VOSM) in Annapolis Junction, Maryland. She is also an amateur veterinary medical illustrator. Additional information about Dr. Lotsikas is available at www.VOSM.com

Lisa Fair has been a veterinary orthopedic technician for 13 years. She is certified in canine massage therapy and has completed all coursework for certification as a canine rehabilitation therapist. She served as Manager of Surgical Services for VOSM until recently. She is now the Director of Marketing and Customer Service for DogLeggs (www.dogleggs.com), manufacturers of external orthopedic coaptation devices and coverage solutions for small animals.





A Review of Canine Cruciate Disease

Part 2

By Peter J. Lotsikas, DVM, Diplomate ACVS, Lisa M. Fair, CMT, CCRT (Candidate), Faith M. Lotsikas, DVM, CCRT
Photos by Peter J. Lotsikas

Surgical stabilization of the cranial cruciate deficient stifle is warranted unless other concurrent medical conditions are prohibitive. In my experience, leaving a stifle unstable generally results in progressive osteoarthritis and compromised limb function, regardless of the breed or size of the patient. While stifle braces are not a substitute for surgical intervention, they are a reasonable alternative when surgery is not an option.

There are three broad categories of surgical stabilization to be discussed: grafting, extracapsular repair, and corrective osteotomies. Within each category, several variations exist. The grafting technique has lost popularity and a recent study concluded this technique to have inferior results; however, it is included here because it is still recommended by some surgeons. Of the remaining techniques, no one technique has proven to be superior to another in terms of technical ease, complication rates, or long-term outcome. Having an experienced and skilled surgeon performing the technique most appropriate for the patient provides the foundation for a successful outcome. Proper post-operative management of the patient is imperative, regardless of the procedure used.

Surgeon experience and skill are very important when evaluating the patient before surgery and evaluating the joint at the time of surgery. The patient's age, size, conformation, activity level, and concurrent medical conditions should be considered when deciding on the appropriate surgical procedure to perform. Regardless of the surgical stabilization recommended, a thorough evaluation of the joint must be performed at the time

of surgery. This can be accomplished via arthroscopy (camera), a "mini" arthrotomy (small incision into the joint), or if needed, a full arthrotomy (opening up the entire joint). Abnormalities of the joint capsule, cruciate ligaments, joint surfaces, menisci, and severity of arthritis should be documented. The remnant of the cranial cruciate ligament should be removed, and in a case of a partial tear, integrity of the remaining band should be evaluated. In some cases, I remove the entire remaining ligament, regardless of its appearance, because it can serve as a source of persistent inflammation and fluid production. This seems to be especially true in the Great Dane and Boxer breeds.

Once the remnant of the cruciate has been addressed, a thorough evaluation of the meniscus must also be performed. Missed mensical tears serve as the number-one observed cause of a "procedural failure" in patients when I am asked to provide a second opinion postoperatively.

In our practice, the meniscus is not just inspected visually but is also probed. Probing the meniscus has been shown to more than double the chance of detecting abnormalities. The damaged portion of the meniscus is removed, with an attempt to preserve

as much of the meniscal rim as possible. Some surgeons recommend a procedure called a meniscal release because this was previously thought to decrease the likelihood of meniscal injury following surgery. However, recent research found this procedure eradicates the natural function of the meniscus. Therefore, a meniscal release can actually lead to progressive osteoarthritis and be detrimental to the overall joint health. While there are a few select circumstances in which I will perform this procedure, I routinely try to preserve all of the meniscus and its attachments. This is particularly important in agility dogs.

Stabilization Techniques

Graft Techniques

Intracapsular repair with a tissue graft is still the most common procedure performed in human cruciate repair, and at one time, it was also the primary method of stabilization for dogs with CCL rupture. However, few veterinary surgeons use this technique today. This technique involves harvesting a strip of tissue from the patient and passing it through the joint in the same pattern and location of the CCL. The graft heals in its new location and gains strength over time. Studies evaluating long-term clinical and radiographic outcomes of this procedure revealed significantly lower weight-bearing and significantly increased osteoarthritic changes and synovitis (inflammation within the joint membrane) as compared to stifles stabilized using other techniques. This is likely due to the inability to adequately protect the graft during the initial phase of healing in the dog. Additionally the graft often has inadequate strength for the de-

mands of the canine stifle's biomechanics and is more susceptible to the degenerative process. Recently, this procedure has been revisited, with interest in using a man-made graft substitute that allows for cellular in-growth. Such a substance has not been shown to be effective in humans and presently there is no data available for this technique.

Extracapsular Techniques

Many technical variations of extracapsular repair for CCL rupture exist and this type of procedure is still among the most popular procedures to date. These techniques passively stabilize the stifle by neutralizing cranial drawer with periarticular fibrosis (scar tissue). The most frequently performed extracapsular technique is the lateral fabellar repair, commonly referred to as a "conventional stabilization." This technique involves passing a non-absorbable synthetic suture (usually fishing line) outside of the joint capsule in a figure-eight or loop pattern around the lateral fabella (a small bone embedded in the gastrocnemius muscle) and through a small hole made in the tibial crest. The suture is either tied by hand or a stainless steel crimp clamp is used to hold the suture material taut. While the suture material will eventually stretch or break, it is meant to provide temporary stabilization to the knee until the body can form organized scar tissue around the suture material that ultimately provides long-term, functional stability. The procedure is widely available, relatively easy to perform, and usually the least expensive of the surgical options. This procedure works well in small- to medium-sized, less active dogs. The major limitations of this

[Hot Dog]



[Cool Dog]





Help your performance dog chill out this summer with Cool Puppy Panels, Chillybuddy Canine Cooling Coats, Cool Beds, Fans, Cool Coats, Kool Collars, Ventlocks, and more! Select Trial Gear from the store menu and then Shade & Cooling.

 www.cleanrun.com

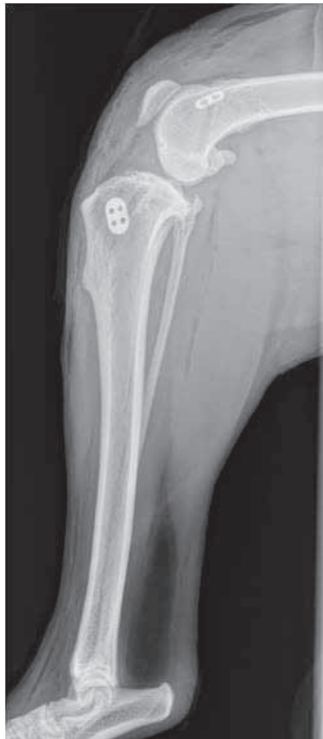technique are: it relies on a small bone as its anchor point, the monofilament that is used has a relatively low tensile strength and has a fair amount of creep (give) to it, and the points of implantation are non-isometric to the cruciate ligament. All these factors can lead to joint laxity during the initial 4-8 weeks of healing that may result in either too much scar tissue formation, which decreases functional range of motion of the stifle, or too little scar tissue, which can lead to persistent instability. These limitations become more obvious in an active performance dog.

The TightRope (TightRope CCL, Arthrex Vet Systems) technique is a new extracapsular stabilization procedure. It differs from conventional extracapsular stabilization in that it can be performed in a minimally invasive manner, provides bone to bone stabilization, and more accurately mimics the natural orientation of the CCL. In addition, it uses a suture material called FiberTape, a Kevlar-like material extensively used in human orthopedic applications. It is much stronger and has less "give" compared with other suture materials currently used in veterinary medicine. Using specific landmarks, the surgeon makes bone tunnels through the femur and tibia. The FiberTape is passed through these tunnels and is secured in place using toggle buttons, much like using a molly bolt in drywall to hang heavy objects. The procedure still relies on the formation of organized scar tissue around the implant for long-term function, but offers superior initial stability compared to the lateral fabellar suture. This procedure appears to be appropriate for a wide variety of dogs including active small and large dogs. Limitations identified for this procedure include patients with excessive tibial slope, underlying medical conditions that may affect scar tissue formation, and abnormal limb alignment. In addition, the risk of infection is slightly higher than is seen with other suture material, as the FiberTape is a braided and nonabsorbable substance that can harbor bacteria. Follow-up data beyond three years is not available for this procedure, but recently published data regarding surgical outcome is positive for the procedure.

Corrective Osteotomies

TPLO

The tibial plateau leveling osteotomy (TPLO) has been the procedure of choice for active large breed dogs over the past 5-10 years, and to date, is the only procedure in veterinary medicine that at one point required specific training and licensing to perform. The procedure involves making a curved cut through

An advertisement for K9 GoDog Total Sports Drink for Dogs. The background is a bright blue sky with white clouds and a green field. A white bottle of the drink is tilted, pouring water into a black cup. A dog's head is visible at the bottom, drinking from the cup. The text "K9 GoDog" is prominently displayed in a colorful, stylized font. Below it, "Total Sports Drink for Dogs" is written in a smaller font. A tagline "BEAT THE HEAT & POWER UP!" is written in large, bold, yellow letters. A list of benefits is provided: "Improve Hydration, Heat tolerance, Mental focus, Energy". Below this, another list of benefits is provided: "Decrease Recovery time, Lactic acid build-up". The Clean Run logo and website address are at the bottom.

BEAT THE HEAT & POWER UP!

Improve

- Hydration
- Heat tolerance
- Mental focus
- Energy

Decrease

- Recovery time
- Lactic acid build-up

Clean Run
www.cleanrun.com



Looking for New Agility Titles?


You can buy them from us!



Tug More Learn More

By Kay Laurence

You *thought* you knew how to play tug with your dog, but do you know how to keep the game going with a quitter? Stop/start/stop with an overeager player? Turn this big-time reinforcer into a big-time shaping tool? 27-page book comes with 28-minute DVD. \$21.95



Chase! Managing Your Dog's Predatory Instincts

By Clarissa von Reinhardt

How do you deal with unwanted predatory behavior? In this fascinating and inspiring book, the author takes readers step by step through her training methods, inviting them to learn about a dog's complex spectrum of behavior and how to maintain as much control as possible over the urge to chase prey. 136 pages. \$16.95



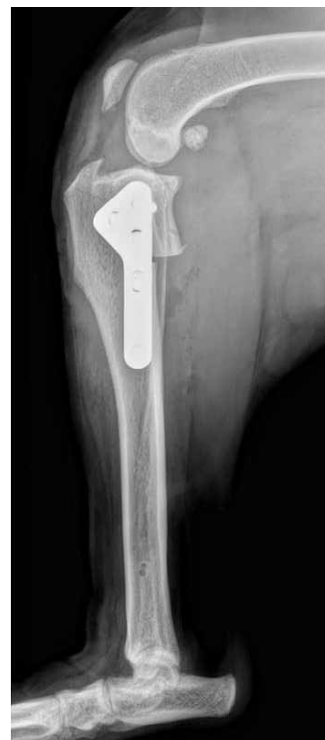How Many Dogs?!

By Debby McMullen

Would you like to live in harmony in a house with multiple dogs? Harmony can be achieved when positive reinforcement training techniques are used, along with proper living-space management. You'll learn how to do this along with techniques for adding new dogs, group training & exercise, and more. 204 pages. \$19.95

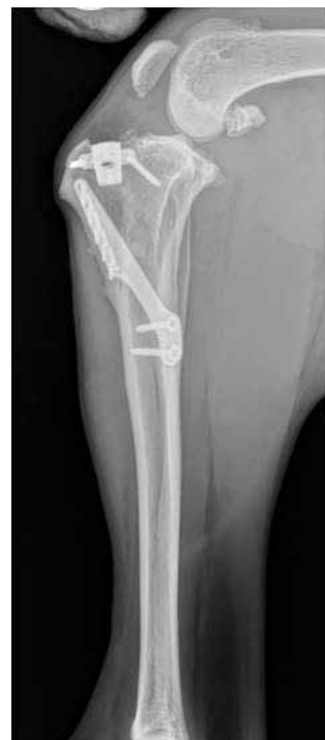Clean Run
www.cleanrun.com

the upper portion of the tibia with a biradial saw blade. The articular or joint component of the tibia is then rotated to achieve a lower angle of the tibial plateau relative to the long axis of the tibia (5°-8° is ideal). The amount of rotation is based on measurements made of the preoperative tibial plateau angle on radiographs. After the tibial plateau has been rotated, a metal plate and screws are applied to hold it in place. The procedure alters the biomechanics of the stifle, placing additional reliance on the caudal cruciate ligament and active muscle stabilizers of the knee. Advantages to this procedure are that it can be used in any size dog with any tibial plateau angle, it has a highly reproducible outcome, and because it relies on bone healing, it is easily assessed on radiographs. Therefore, once the bone is healed on radiographs, it provides a documentable permanent "fix." Limitations of this procedure include the highest learning curve for the surgeon of any of the procedures, the potential for serious complications exist (although not common), and it may not be suitable in geriatric patients or patients with poor bone quality.



TTA

The TTA technique is a newer corrective osteotomy that was developed in Europe shortly after the TPLO began gaining popularity in the U.S. The procedure involves making a linear cut behind the tibial tuberosity (top front portion of the tibia). The tibial tuberosity is then advanced so that the patellar tendon is perpendicular to the tibial plateau. The advanced portion of bone is held in place with a titanium cage (that acts as a spacer between the two bones) and a titanium plate. Once anchored, a bone graft is applied to the space between the bones to promote bone healing. The procedure relies on neutralizing tibial thrust by changing the force through the knee to be parallel to the patellar tendon, which gives a biomechanical advantage to the quadriceps muscles and subsequently stabilizes the stifle. Biomechanical studies would suggest that the TTA, if per-



formed properly, may neutralize the forces exerted on the stifle and protect the meniscus better than the TPLO. The procedure is also less technically demanding than the TPLO, which results in more room for surgeon error. However, the TTA is one of the least versatile procedures, and is best used in patients with a low tibial plateau angle and relatively straight tibias. The advancement of the tibia can also change the visual appearance of the tibia, particularly in breed dogs with short hair, which may be a disadvantage in the show ring. In addition, like the TPLO, the TTA also carries a risk of major complications. Infections of the spacer cage, which although uncommon, can be extremely challenging to resolve without loss of stifle stabilization.

Post-operative Management

As mentioned earlier, post-operative care is imperative to a successful outcome regardless of the repair technique used. An optimally functioning limb requires that the joints be pain free, that range of motion is preserved, and that muscle mass is symmetrical between limbs. In our practice post-operative management is a collaboration of the surgeon, rehabilitation therapist, and owner and has four distinct phases. Rehabilitation therapy objectives and guidelines are outlined in the table.

Post-Op Period	Goals of Therapy	Therapeutic & Rehabilitation Modalities
Immediate (during hospitalization)	<ul style="list-style-type: none"> Decrease swelling and effusion Increase comfort 	<ul style="list-style-type: none"> GameReady™ (treatment device providing cryotherapy with compression) Intravenous antibiotics, non-steroidal anti-inflammatory (NSAID) and pain medications
Day 3-5 through Day 14	<ul style="list-style-type: none"> Decrease swelling and effusion Increase comfort Maintain range of motion Increase weight bearing 	<ul style="list-style-type: none"> Cryotherapy Passive range of motion Rehabilitation therapy: manual techniques, cold laser, and/or therapeutic ultrasound, client education Weight-bearing exercises Oral NSAID and pain medications
Week 3 through Week 6-8	<ul style="list-style-type: none"> Increase range of motion Improve weight bearing Increase muscle mass 	<ul style="list-style-type: none"> Passive range of motion Rehabilitation therapy Weight-bearing exercises Strengthening exercises Leash walks of incrementally increasing length
Week 6-8 through Week 10-12	<ul style="list-style-type: none"> Increase muscle mass Improve limb function Proper tracking and proprioception 	<ul style="list-style-type: none"> Rehabilitation therapy: underwater treadmill Increase challenge of strengthening exercises Leash walks of incrementally increased length Hill work and walks on varying terrain Underwater treadmill therapy
Week 10-12 through Week 14-16	<ul style="list-style-type: none"> Symmetry in muscle mass Normalized limb function Proper tracking and proprioception Begin retraining and conditioning* 	<ul style="list-style-type: none"> Rehabilitation therapy: underwater treadmill Controlled off-leash activity Jogging Easy combinations and straight lines
Week 14-16 through Week 18-20	<ul style="list-style-type: none"> Retraining and conditioning 	<ul style="list-style-type: none"> Incrementally introduce more difficult equipment, turns with jumps, and speed
Week 22-24	<ul style="list-style-type: none"> Introduction to full agility activities 	<ul style="list-style-type: none"> A-frame and tunnels

* For all canine athletes, we recommend analysis of training methods and competition styles before trialing to help minimize the risk of developing compensation injuries and prevention of new injuries.



Take your training where it's never gone before


The Ready Jump is a portable, competition-quality, 4' wide jump that you can take *anywhere*. It opens or closes in under 15 seconds and stores easily with no loose pieces. The Ready Jump features Clip and Go jump cup strips so it has cups every 2", from 4" up to 26". It's so easy to use, there's no excuse not to take the show on the road.



Clean Run®

Available exclusively from www.cleanrun.com and www.ClipAndGoAgility.com

Derrett Fans, Rejoice!



Not a fan yet?
Well, get busy!



In *Great Dog Great Handler: The Winning Combination*, Greg goes into far more depth regarding the reasons and theory behind his system. He provides clear and precise rules to enable handlers to understand each handling maneuver, including the where, how, and why. This latest DVD includes advanced training drills to improve your dog's understanding and his speed and turning ability, detailed instructions on improving your footwork, slow-motion shots to show precise timing of maneuvers, and an explanation of handling mistakes.

Clean Run
www.cleanrun.com

A strong relationship between owner, surgeon, and rehabilitation therapist is key to a successful outcome.

Prognosis

In general, we are able to return 90%-95% of patients back to peak performance in 4-6 months following surgery. We have found that weekly rehabilitation therapy with a professional therapist in addition to a stringent home exercise plan can speed recovery by 3-4 weeks and allow patients to return to competition as early as 3 months following surgery.

Individual results and recovery time will vary between patients, and we are constantly investigating and developing new protocols to hasten return to function.

With regard to complications, major complications are fortunately very uncommon and most can be addressed without major consequence to long-term function. The two most common surgical complications encountered are infection and subsequent meniscal injury following stifle stabilization. Infections are almost always derived from the patient as a consequence of licking the incision and are best prevented with an Elizabethan collar, rather than treated. Meniscal injury following stifle stabilization occurs in 4%-8% of patients and can occur months to years following surgery. Meniscal injuries are routinely treated arthroscopically and the patient can return to function 4-6 weeks following the procedure.

Conclusion

At VOSM, all the aforementioned procedures are available and discussed with owners. I personally perform over 300 knee surgeries a year, and have the most reproducible outcomes with return to full agility function with the TPLO and TightRope stabilization. Success can vary with each individual surgeon's preferences and expertise.

As mentioned, a strong relationship between owner, surgeon, and rehabilitation therapist is key to a successful outcome. 🐾

Disclosure: Dr. Peter J. Lotsikas is a paid clinical instructor for Arthrex, Inc.

Dr. Peter Lotsikas is a Diplomate of the American College of Veterinary Surgeons. He graduated with a BS degree in Biology from Virginia Tech and a DVM degree from the Virginia-Maryland Regional College of Veterinary Medicine. He then completed a general small animal internship at Kansas State University, followed by a surgical internship at Dallas Veterinary Surgical Center. Dr. Lotsikas received his formal surgical residency training at Iowa State University. He now practices at the Veterinary Orthopedic & Sports Medicine Group (VOSM) in Annapolis Junction, Maryland. Additional information about Dr. Lotsikas is available at www.VOSM.com

Dr. Faith Lotsikas earned her veterinary degree from the Virginia Maryland Regional College of Veterinary Medicine. She has always had a strong interest in whole pet wellness. For that reason, she became a certified canine rehabilitation therapist through the Canine Rehabilitation Institute. She now practices with her husband at the Veterinary Orthopedic & Sports Medicine Group (VOSM) in Annapolis Junction, Maryland. She is also an amateur veterinary medical illustrator. Additional information about Dr. Lotsikas is available at www.VOSM.com

Lisa Fair has been a veterinary orthopedic technician for 13 years. She is certified in canine massage therapy and has completed all coursework for certification as a canine rehabilitation therapist. She served as Manager of Surgical Services for VOSM until recently. She is now the Director of Marketing and Customer Service for DogLeggs (www.dogleggs.com), manufacturers of external orthopedic coaptation devices and coverage solutions for small animals.